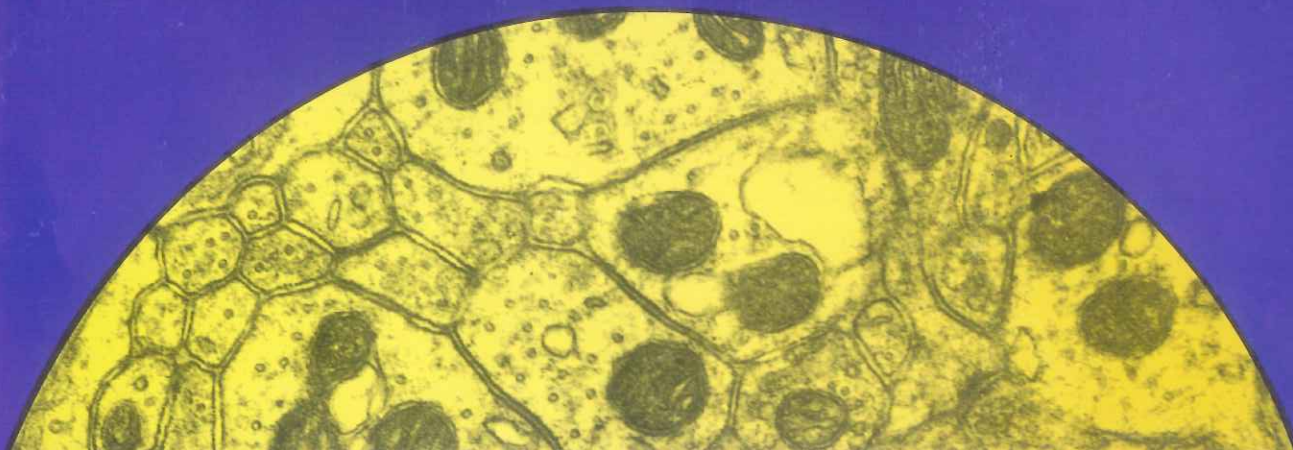


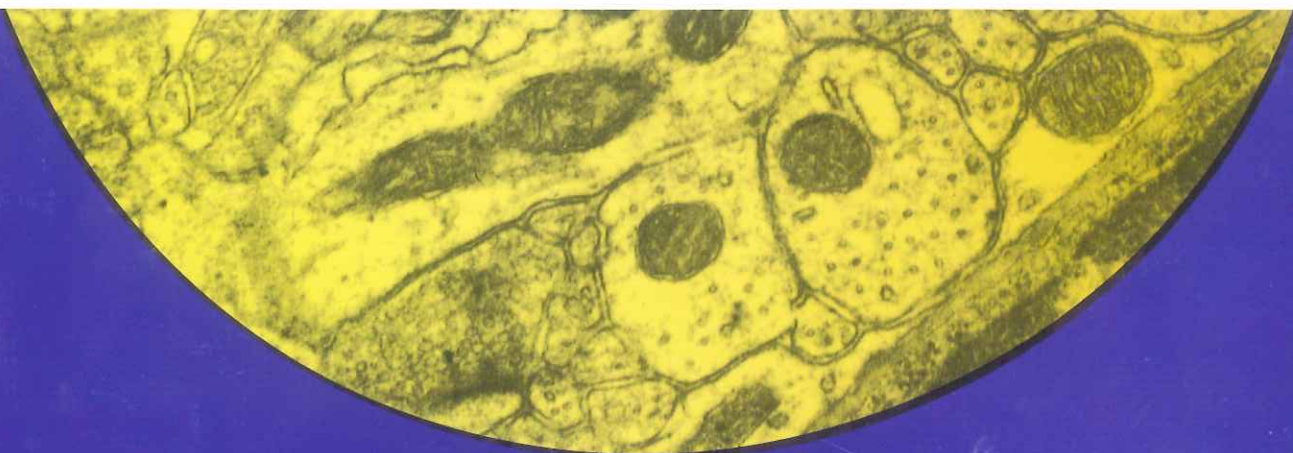Научно-теоретический  
медицинский  
журнал

*ISSN 1026-3543*



**МОРФОЛОГИЯ**

**MORPHOLOGY**



Приложение

**3**  

---

**2018**

RUSSIAN ACADEMY OF MEDICAL SCIENCES

INTERNATIONAL ASSOCIATION OF MORPHOLOGISTS

SCIENTIFIC THEORETICAL MEDICAL JOURNAL

# MORPHOLOGY

ARCHIVES OF ANATOMY, HISTOLOGY, AND EMBRYOLOGY

Founded in June 1916 by A. S. Dogiel

According to the decision of Presidium of Higher Attestative Commission of Russian Ministry of Education and Science, «Morphology» is included into the List of leading peer-reviewed scientific journals, in which main scientific materials of doctoral and candidate's theses should be published

«Morphology» is abstracted by Scopus, Russian Index of Scientific Citation (RISC) on the basis of eLIBRARY.RU scientific electronic library

VOLUME 153

**3 (Supplement)**

ST. PETERSBURG • «AESCULAPIUS» • 2018

## PECULIARITIES OF TATTOO PIGMENT DISTRIBUTION IN THE SKIN

Kalashnikova S. A. <sup>1\*</sup>, Karymov O. N. <sup>2</sup>,  
Polyakova L. V. <sup>1</sup>

<sup>1</sup> Pyatigorsk Medical Pharmaceutical Institute of Volgograd Medical State University of the Ministry of Health Care of Russia, Pyatigorsk; <sup>2</sup> Moscow Scientific and Practical Center of Dermatovenerology and Cosmetology of the Department of Health of Moscow, Moscow

\* kalashnikova-sa@yandex.ru

**Key words:** tattoo, layers of skin, pigment for tattoo

**Aim.** To describe the features of tattoo pigment distribution in the skin.

**Material and Methods.** An experimental study was carried out on 30 nonlinear white rats (males) who were tattooed with black ink. The animals were sacrificed on 10<sup>th</sup> day. The skin was sampled, processed, and stained with hematoxylin and eosin according to the standard protocol for the pathohistological examination.

**Material and Methods.** In the early stages after tattooing, the accumulation of the pigment was observed in the superficial layers of derma, particularly in the perivascular area of the papillary layer. The pigment was distributed in a various pattern, from the relatively large well-distinguishable granules directly under the epidermis to the «dust-like» infiltration of the papillary dermis. Loose connective tissue of papillary layer showed the features of edema with uneven filling of the blood vessels. The margination of leukocytes in the blood vessels was observed. The degree of the epidermis adherence to the papillary layer of dermis varied, and it depended on the severity of the skin edema. In some skin areas there were the clefts between the basal layer of epidermis and the papillary layer of dermis. In the reticular layer of dermis, the foci of leukocyte infiltration mainly of neutrophils with few eosinophils and lymphocytes were identified.

**Conclusions.** The described pattern of pigment distribution within the tattooed skin showed the irregular distribution of ink and a pronounced inflammatory reaction to the injected pigment in the early tattoos.

## REACTION OF THE LYMPHATIC SYSTEM TO TATTOOING

Kalashnikova S. A. <sup>1\*</sup>, Karymov O. N. <sup>2</sup>,  
Polyakova L. V. <sup>1</sup>

<sup>1</sup> Pyatigorsk Medical Pharmaceutical Institute of Volgograd Medical State University of the Ministry of Health Care of Russia, Pyatigorsk; <sup>2</sup> Moscow Scientific and Practical Center of Dermatovenerology and Cosmetology of the Department of Health of Moscow, Moscow

kalashnikova-sa@yandex.ru

**Key words:** tattooing, lymph node, tattoo pigment

**Aim.** To describe the regional lymphatic system reaction to the tattooing.

**Material and Methods.** Under anesthesia, tattooing was performed in the back region of 30 nonlinear white rats (males). The experimental animals were sacrificed on the 10<sup>th</sup> day after tattooing. The samples of tattoo areas and regional lymph nodes were processed and stained with hematoxylin and eosin in compliance with the standard protocol and histologically examined.

**Results and Discussion.** The pathohistological examination of the lymph nodes showed that the main accumulation of the tattoo pigment occurred along the lymph node sinuses. The ink accumulation was mainly detected in the marginal sinus and medullary sinuses as well. In the lymph nodes, the boundary between the cortex and medulla was not clearly observed due to the heavy pigment infiltration. In the cortex, the follicles with poorly-defined germinal center were identified. The cellular component of the follicles in the cortex included lymphocytes, plasma cells and few macrophages. In the periphery of the germinal centers the pigment deposits were scanty. In the medulla, the pigment deposits were identified along the cords and sinusoids.

**Conclusions.** The lymphatic system was involved into the spread of the tattoo pigment via the regional lymph vessels and lymphatic nodes.

## POST-TRAUMATIC USE OF ERYTHROPOETIN AND LOW DOSE IONISING RADIATION TO PREVENT SECONDARY DAMAGE IN SPINAL CORD TRAUMA

Kaptanoğlu Erkan <sup>1</sup>, AtasoyBeste Melek <sup>2</sup>,  
Bozkurt Süheyla <sup>1</sup>, Güvenç Yahya <sup>1</sup>, Pınar  
Ertuğrul <sup>1</sup>, Şahin Ali <sup>1</sup>, Surucu Selcuk <sup>3</sup>

<sup>1</sup> Marmara University, Institute of Neurological Sciences, Istanbul; <sup>2</sup> Marmara University, Faculty of Medicine, Istanbul; <sup>3</sup> Koc University, School of Medicine, Istanbul

**Key words:** spinal cord injury, erythropoietin, ionizing radiation, trauma

**Background.** As clinical outcome of acute traumatic spinal cord injury, many patients are forced to sustain their lives with paralysis. These patients face very difficult medical and social care and many complications over the years. In our study.

**Aim.** It was planned to use combined treatment modality of erythropoietin and ionizing radiation in the traumatic spinal cord injury model in rats. This study is approved by the Experimental Animal Research Ethical Committee of Marmara University.

60 Sprague Dawey rats were divided into following groups:

Trauma	10
Trauma+IR60	10
Trauma+IR200	10
Trauma+EPO	10
Trauma+EPO+IR60	10
Trauma+EPO+IR200	10

**Material and Methods.** Spinal trauma was created by free fall of 50 g weight on T8–10 segments. Epobel was administered 5000 iu/0.5 ml by iv route 1 hour after the trauma. Ionising radiation was applied at 60 and 200 cGy doses 2 hour after the trauma.

**Results and Discussion.** The results were evaluated by locomotor tests, ultrastructural tissue analysis, Tunel apoptosis test, ependymal stem cell identification, gliosis scores, proliferation analysis, enolase and S100 beta analysis methods.

**Conclusions.** Combination of eritropoetin with low dose radiation is beneficial for protection from secondary effects of spinal cord trauma.

#### THE ASSESSMENT OF THE GROWTH PROCESSES OF LATVIAN PRESCHOOL CHILDREN IN COMPARISON WITH WHO GROWTH STANDARDS

*Karklina H., Krumina D., Knipse G.*

University of Latvia, Riga, Latvia

**Key words:** children, physical activity, body mass index (BMI), WHO Growth Standards

**Background.** Due to worldwide growing problem of overweight and obesity the World Health Organization (WHO) has recently issued recommendations and guidelines for regular collection of data on weight, height and waist and hip circumference in children.

**Aim.** The aim of the research is to determine body composition of Latvian children in the last decade and to compare most important anthropometric characteristics of the Latvian children with the WHO Growth Standards 2007.

**Material and Methods.** Research was made using anthropometrical and questionnaire methods (about their lifestyle) trying to conclude if the increase of the excessive body mass and adiposity in Latvian preschool and a youngest grade school-children is similar to one in other countries in the world, because the risk of health problem development increases in proportion with the body mass index enlargement or decrease. Total of 1235 healthy children were surveyed from all regions and different socio-economic groups.

**Results and Discussion.** After loosing the independence in year 1940 and especially in the post war period, the ethnic situation in Latvia has had major changes — due to emigration the amount of Latvian, and other nationality inhabitants in the country significantly decreased. This also includes a high number of multi national marriages, majority of them between Russians and Latvians. The correlation between BMI and fatness in children is influenced by age, sex, pubertal status and ethnicity. Since 2007 WHO growth reference charts was preva-

lent distributed, but child growth depends from geographic area and social and economic conditionals.

**Conclusions.** Comparing Latvian schoolchildren BMI values with the WHO Growth Standards, we can see that BMI percentiles values are significantly different. The WHO growth standards do not reflect the phenotypic range of the Latvian preschool and school children and we recommend using the Latvian growth curves (1998) to evaluate the growth processes of the Latvian children.

#### ULTRASONIC DOPPLEROGRAPHY APPLICATION FOR THE EVALUATION OF THE ARTERIAL PALMAR ARCHES FORMATION TYPES

*Khalilov M. A., Moshkin A. S., Alekseev A. G.*

I. S. Turgenev Orel State University, Orel, Russia  
sanderlexx@yandex.ru

**Key words:** ultrasound dopplerography of the upper limbs arteries, palmar arcs, radial artery, ulnar artery

**Aim.** The study is devoted to the blood flow analysis in the basins of the radial and ulnar arteries and the evaluation of the prevalence of the palmar arcs formation types.

**Material and Methods.** The research was performed on a dispensary basis using the technique of ultrasound dopplerography supplemented with a functional Alain probe on the Samsung Medison R7 and Aloka SSD 3500 devices. 50 patients of both sexes aged from 32 to 85 years (mean age of 51 years) were examined. Data analysis was processed with Microsoft Excel 2007 software.

**Results and Discussion.** It was found that the average diameter of the radial and ulnar arteries in the total sample remains constant and is practically equal for the both radial artery — 1.77 mm (minimum diameter 1.3 mm, maximum — 2.7 mm) and ulnar — 1.78 mm (minimum diameter 1.4 mm, maximum — 2.9 mm). Peak blood flow rates obtained with pulsed wave doppler ultrasonography were also characterized for both arteries with a small difference, in the radial artery — 31.16 cm/sec (minimum speed is 5.6 cm/sec, maximum — 62.4 cm/sec), in the ulnar — 34.45 cm/sec. (minimum speed is 5.2 cm/sec, maximum — 77.55 cm/sec). The median for the both arteries estimation was also not significantly different: for the radial artery — 31 cm/sec, for the ulnar artery — 33.8 cm/sec.

When the Allen test was performed, it was found that in 50% of cases the pronounced blood supply of the palmar arcs from the ulnar arteries basin was observed, in 18% of cases it was registered in the radial arteries, and in 32% as a result of the measurement there was no significant change in the blood flow parameters or the result was doubtful.


**Conclusions.** As a result of observation, the dominant role of the ulnar artery in the formation of arte-

**PROCEEDINGS OF THE 10<sup>th</sup> INTERNATIONAL SYMPOSIUM  
ON CLINICAL AND APPLIED ANATOMY (ISCAA)**

**Moscow, September 13–16, 2018**

Edited by

Professor *S. S. Dydykin*,  
Professor *I. V. Zadnipyriy*,  
Professor *D. N. Lyashchenko*,  
Associate Professor *Y. L. Vasiliev*



**ISCAA 2018**

**10<sup>TH</sup>**

**International Symposium  
of Clinical and  
Applied Anatomy**



SECHENOV  
UNIVERSITY



**September 13-16, 2018**

**Sechenov University**

**Moscow - Russia**

**Program**

---

# CERTIFICATE OF PARTICIPATION

---



THIS CERTIFICATE IS PRESENTED TO

*Surucu Selcuk*

IN RECOGNITION OF YOUR **PARTICIPATION**  
IN THE **10 TH INTERNATIONAL SYMPOSIUM OF CLINICAL  
AND APPLIED ANATOMY (ISCAA)**



**10<sup>TH</sup>**

International  
Symposium of Clinical  
and Applied Anatomy

---

Honorable President of X ISCAA  
Professor Petr Glybochko  
Rector, Sechenov University,  
Moscow, Russia